

Evaluation of the effect of rapid maxillary expansion on the respiratory pattern using active anterior rhinomanometry: Case report and description of the technique

Edmilsson Pedro Jorge*, Luiz Gonzaga Gandini Júnior**, Ary dos Santos Pinto***, Odilon Guariza Filho*, Anibal Benedito Batista Arrais Torres de Castro****

Abstract

The aim of the present investigation is to evaluate the effect of rapid maxillary expansion (RME) on the respiratory pattern. A clinical case is presented to describe how patients with atresic maxilla and respiratory problems can benefit from rapid maxillary expansion. The article highlights that the health professional, mainly the Orthodontist and the Otorhinolaryngologist, may use complementary exams to diagnose a mouth breather patient.

Keywords: Active anterior rhinomanometry. Rapid maxillary expansion. Total nasal resistance. Respiratory pattern. Mouth breather. Upper airway.

INTRODUCTION

Nasal breathing is the only physiologically normal breathing pattern seen in humans. When for some reason, the individual has any difficulties of breathing through the nose, it complements or replaces the nasal breathing by mouth breathing.¹⁵

The diagnostic methods to determine the breathing pattern of an individual are controversial. However, the effects of nasal respiratory obstruction are not fully understood in the development of malocclusion and facial growth.

Although much has been researched about the relationship between respiration and craniofacial growth, many questions still remain unanswered, because of numerous variables including genetic predisposition and environmental influences, as each individual has its own way to adapt for the resulting impact of the alteration of normal breathing pattern.^{11,20,27}

The importance of studying the nasal breathing and its alterations is fundamental to the orthodontist, because the nasal breathing disorders may impact negatively on the development

* MSc in Orthodontics, Department of Orthodontics and Pediatric Dentistry, School of Dentistry, University of São Paulo (FOUSP) and PhD in Orthodontics, Department of Pediatric Dentistry, School of Dentistry, São Paulo State University (UNESP - Araraquara).

** Assistant Professor, Department of Pediatric Dentistry, School of Dentistry, São Paulo State University (UNESP - Araraquara).

*** Adjunct Professor, Department of Pediatric Dentistry, School of Dentistry, São Paulo State University (UNESP - Araraquara).

**** Adjunct Professor, Department of Otolaryngology and Human Communication Disorders, Federal University of São Paulo (UNIFESP).

of occlusion^{19,20} and on facial growth.^{11,25}

For over a century, some researchers were interested in evaluating the effect of rapid maxillary expansion (RME) on nasal morphology and function. This procedure, introduced by Angell¹ changes the shape of the jaw, opening the palatal suture and other facial sutures. Numerous studies have shown that the outcome of this procedure causes changes in the transverse dimension of the maxilla and nasal cavity, providing an improvement in breathing.^{2,3,8,9}

There are reports of scientific studies that the breathing pattern of an individual with reduced naso-respiratory function may be improved by rapid maxillary expansion, since the increase in nasal cross-sectional area leads to a decrease in nasal resistance increasing the airflow.^{3,4,10,12,14} However, it is necessary to maintain a minimum level of nasal resistance in order to provide respiratory gas exchange occurring in the pulmonary alveoli.²⁹

Subtelny²⁶ associated oral breathing to unfavorable dentofacial development, and reported that, for normal breathing to exist the proper use of the nasal cavity and nasopharyngeal space was necessary. And that an abnormal increase of the structures within these anatomic areas, such as hypertrophy of the turbinates and / or hypertrophy of the adenoid tissue, could cause a blockage of air passage through the upper airway. Thus, if the obstruction was of sufficient size to prevent nasal breathing, the result could be a way of adapting to mouth breathing.

The reduction of naso-respiratory function may be caused by several etiologic factors, which may be located in the bucopharynx, nasal cavity or nasopharynx.^{15,16,21,23} However, the most commonly nasal obstructions encountered, that can cause an increase in nasal resistance are: pharyngeal tonsil hypertrophy, hypertrophy of palatine tonsils, hypertrophy of the turbinates, nasal septum deviation and allergic rhinitis.^{5,15,16,31}

For Watson Jr. et al,³¹ most patients with re-

spiratory nasal resistance above 4.5 cmH₂O/L/sec. are mouth breathers, although for Vig et al,²⁷ nasal respiratory resistance of 4.5 cmH₂O/L/sec., is a critical value to distinguish the nasal from the oral breathers. McCaffrey and Kern¹⁸ report that the symptom of nasal obstruction occurs when the value of total nasal resistance is greater than 3 cmH₂O/L/sec. Warren et al³⁰ described that when the total nasal resistance is high, around 4.5 cmH₂O/L/sec, the vast majority of individuals are regarded as mouth breathers. The values obtained through the active posterior rhinomanometry and nasal breathing in patients with nasal obstruction are different—on average 1.86 cm H₂O/l/sec. and 3.05 cmH₂O/L/sec., respectively.¹³

Another method used to quantify the respiratory pattern is by measuring the nasal cross-sectional area. However the limit of change of oral to nasal breathing is very close,²⁸ about 0.40 to 0.45 cm². About 97% of individuals with nasal cross-sectional area smaller than 0.4 cm² have some kind of mouth breathing,²⁸ or a nasal cross-sectional area equal to or less than 0.4 cm² gives a nasal respiratory resistance from 0.5 to 4.7 cmH₂O/L/sec.¹⁴ Thus, the extremely high breathing resistance requires the individual to open his mouth about 0.4 to 0.6 cm² to reduce it and achieve normal values compatible with breathing, from 1.9 to 2.2 cmH₂O/L/sec.³⁰

Recently, with technological advances and the increasing interest of orthodontists and otolaryngologists for this topic, new techniques try to quantify and evaluate more objectively the effect of rapid maxillary expansion on the respiratory pattern.^{22,24} To MacCaffrey and Kern;¹⁸ Kern;¹⁷ Clement,⁶ one of the more common and physiologic diagnostic methods used to study resistance and conductance of the nasal airway is the active anterior rhinomanometry, which was standardized in 1968 by Cottle,⁷ and consists of an aerodynamic test in which the pressure and nasal flow are quantified.

Therefore, the purpose of this article was to evaluate whether there was a change in the patient's breathing pattern which showed transverse deficiency of the upper arch and had indication for rapid maxillary expansion.

RAPID MAXILLARY EXPANSION APPLIANCE

The device used for rapid maxillary expansion was a tooth-mucosa supported appliance, called modified Haas⁸ appliance. The device was made of acrylic resin with an expansion screw of 11 mm placed on the center of the device. Orthodontic bands were used on the first premolars and first permanent molars, which were soldered onto a length of stainless steel wire of 1.2 mm that extended from the cervical portion of the lingual surface of the first molar to the lateral incisor.

Installation and activation of the rapid maxillary expansion device

A caucasian, male patient, aged 11 years and 6 months, sought the orthodontic clinic with the desire of improving his smile and teeth position. During clinical examination, it was found that the patient presented an Angle Class II, division 1, malocclusion, bilateral posterior crossbite in the region of the first pre-molars, atretic pre-maxillary, mild anterior upper and lower crowding with lack of space for the upper left canine and lower first premolars. In this first appointment, the patient reported that he was a mouth breather, thus, the same was referred to the otolaryngologist.

In the first phase of treatment a rapid maxillary expansion modified Haas appliance was planned. On the day of appliance installation all the recommendations were explained to the parents, regarding oral hygiene and the device's mode of activation. However, the activation only started the next day.

Concerning oral hygiene, it was explained to the patient that always after meals he should perform his dental hygiene, brushing his teeth

and the appliance. He was advised to use a 20 ml plastic syringe with water, to perform the removal of food remnants that remained between the palate and the appliance. In relation to the activation of the appliance, the patient's guardian was called, and requested to sit beside the patient so all necessary guidelines were passed, and also to observe how to activate the expander. First, it was explained that whenever he was performing the procedure, the activation key should be tied with dental floss, around one of the fingers of the person who would be performing the activation. This procedure is necessary in order to prevent accidental swallowing of the key. The parent was oriented that, for the activation of the device, the screw should be turned with the key from front to back, two quarters backwards in the morning and two quarters backwards in the evening, summing a full turn of the screw per day. After the initial explanation, we performed the activation of the screw, and then immediately asked his father to perform the same procedure in order to observe that he would have no doubts in carrying out the activation at home. After elucidation of all doubts, the patient was dismissed.

Consultations were scheduled every three days for periodic control of expansion and to observe whether activation was being conducted properly.

ACTIVE ANTERIOR RHINOMANOMETRY

Type of device and calibration

The appliance used for the patient's active anterior rhinomanometry was a rhinomanometer RM 302 Berger, composed of two channels, allowing simultaneous assessment of flow and pressure in each nasal cavity during breathing. This equipment has two transducers, two graphic recorders, a flow meter (pneumotachograph), a pressure gauge and two olives. The flow olive had an outlet diameter of 7 mm, while the pressure olive had an outlet diameter of 5 mm. The



FIGURE 1 - Extraoral photographs: **A)** profile view, **B)** front view, **C)** opening of diastema between upper central incisors.

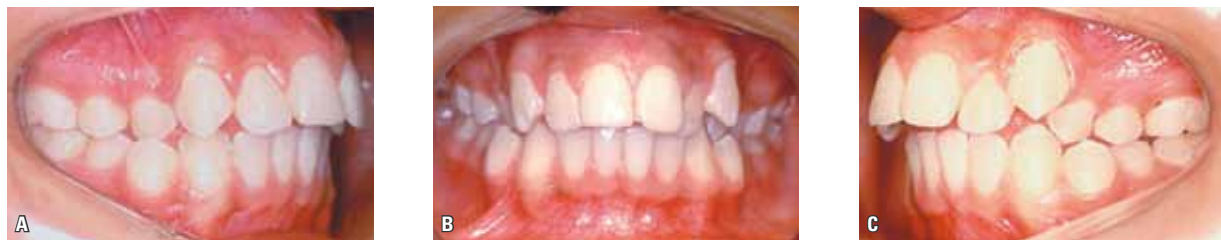

FIGURE 2 - Intraoral photographs: **A)** right lateral view, **B)** front view, **C)** left lateral view.

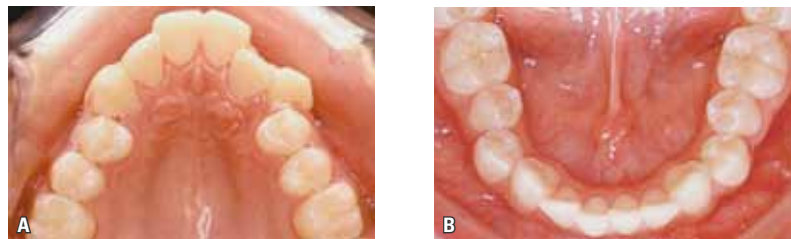

FIGURE 3 - Intraoral photographs: **A)** upper occlusal view, **B)** lower occlusal view.

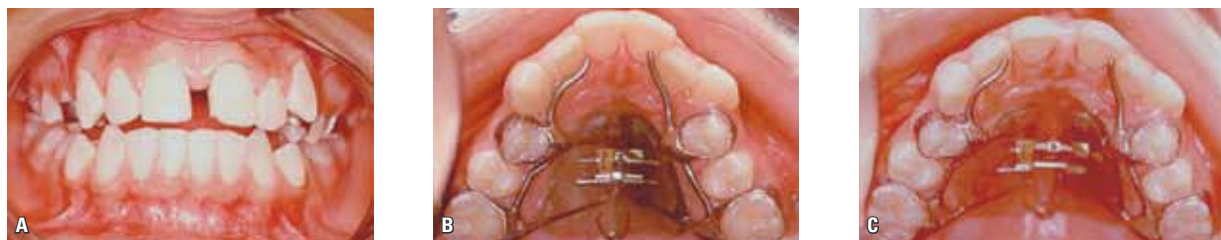

FIGURE 4 - Intraoral photographs: **A)** front view, with opening of diastema between upper central incisors, **B)** upper occlusal view, with modified HAAS palatal expander in position and **C)** upper occlusal view, after opening of the midpalatal suture.

recordings were made with writing needles on common graph paper at a speed of 10 mm/sec.

Device calibration had the following standardization: the flow meter was calibrated so that each 5 mm of deviation from baseline on the paper matched the flow of 10 liters/minute, while the pressure gauge was calibrated so that each 5 mm of deviation on the tracing was equivalent to 20 mm H₂O.

Before conducting the patient examination the rhinomanometer was taken to a specialized company (Eletromedicina Berger Indústria e Comércio™, Brazil), for review and calibration.

Examination

Before the examination, the patient was asked if he had a cold, otherwise the examination was not performed and another date would be scheduled.

The procedure was fully explained to the patient, who was instructed to sit comfortably on a chair, breathing quietly through the nose and keeping his mouth closed. The examination was performed at room temperature and after the patient had rested for 30 minutes.⁶

Initially, the exam was conducted under normal conditions, without the use of topical vasoconstrictor. It always started by the right nasal cavity. The olive that was connected to the pneumotachograph was placed in the right nostril and the olive connected to the pressure gauge was placed in the left nostril. Thus the flow (V) and

pressure (P) were obtained from the right nostril and then reversing the positions of the olives, the left nasal cavity was evaluated.

The olive connected to the flow meter as well as that connected to the pressure gauge were fitted perfectly to the nostrils, in order not to cause deformation of the lobe and nasal air escape. With this purpose, the examination was always performed by the examiner, who held the olives into the desired positions, during acquisition.

At the beginning, three respiratory cycles were recorded for the patient to become familiar with the exam and breathe normally, then ten respiratory cycles were done for each nasal cavity.

Later 3 drops of a topical vasoconstrictor solution (oxymetazoline hydrochloride 0,05%) were applied in each nostril of the patient, and after 15 minutes, the test was repeated as described above.

Thus the values of flows and pressures in each nasal cavity were obtained and recorded. From this data, we calculated the unilateral nasal resistance and total nasal resistance of the patient

CALCULATION OF UNILATERAL AND TOTAL NASAL RESISTANCE

Calculation of unilateral nasal resistance

To calculate the unilateral nasal resistance, the sensitivity of rhinomanometer RM - 302 was the following:

- » Pressure: each 5 mm variation of the baseline corresponded to 20 mm of water (mm/H₂O)
- » Flow: each 5 mm variation of the baseline was equal to 10 liters per minute (l/min.)

To obtain the actual values of pressure and flow from the tracings every millimeter of the tracing was multiplied by the following factors:

- » Pressure tracing, every millimeter was multiplied by 4
 $1 \text{ mm} \times 4 = 4 \text{ mm H}_2\text{O}$
- » Flow tracing: every millimeter was multiplied by 2
 $1 \text{ mm} \times 2 = 2 \text{ mm H}_2\text{O}$



FIGURE 5 - Device used to perform the active anterior rhinomanometry exam. Rhinomanometer RM - 302 from Berger™.

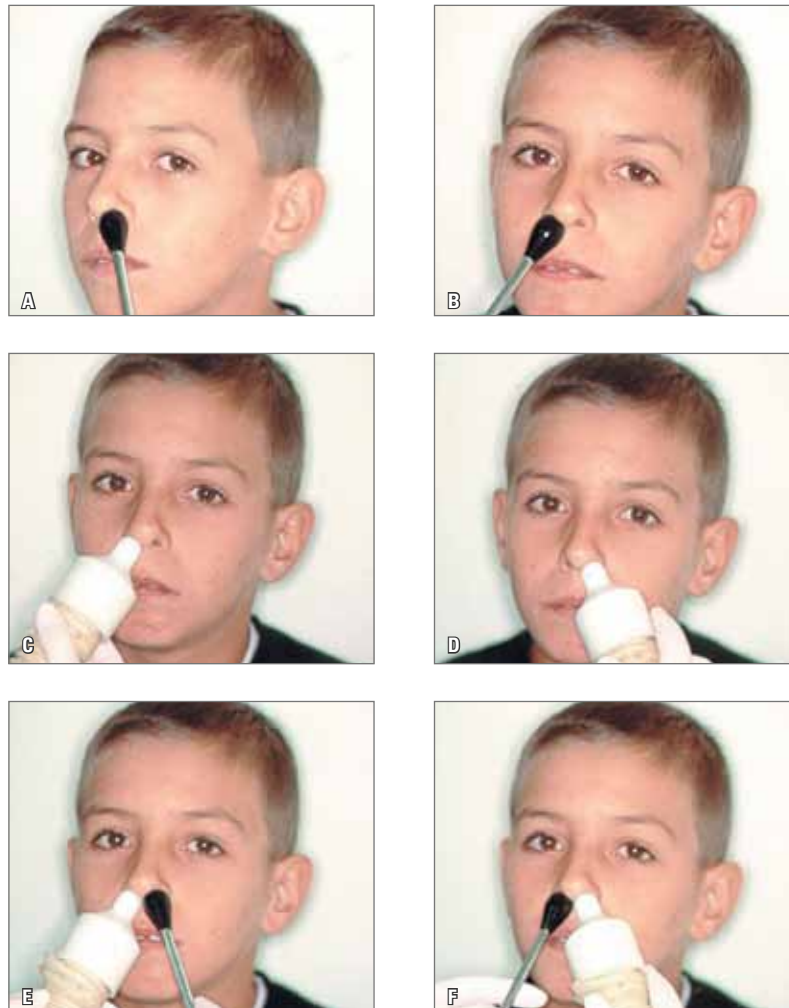

FIGURE 6 - Performing the active anterior rhinomanometry exam: **A)** Obtaining the right nasal pressure, **B)** Obtaining the left nasal pressure, **C)** Obtaining the right nasal flow, **D)** Obtaining the left nasal flow, **E)** Simultaneous obtainment of pressure and right nasal flow and **f)** Simultaneous obtainment of pressure and left nasal flow.

The formula used to calculate the unilateral nasal resistance was as follows:^{6,18}

$$R = \frac{\Delta P}{V}$$

In this manner the left and right nasal resistance were calculated without vasoconstrictor, and after with vasoconstrictor.

For Cottle,⁷ a tracing pattern characterized by regular rhythm, amplitude and frequency observed in normal subjects without complaints of nasal obstruction, the flow:pressure ratio (V/P) would be 20/20 or 24/18.

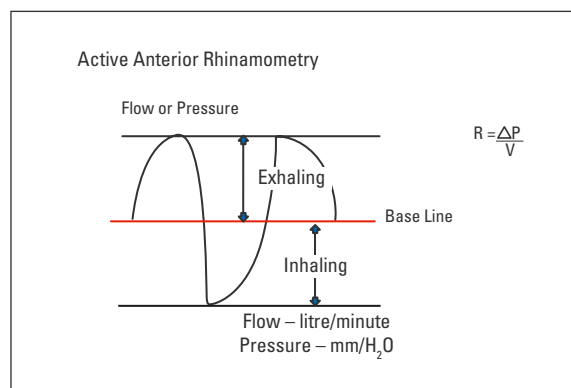


FIGURE 7 - Rhinomanometric trace showing expiratory and inspiratory curves.

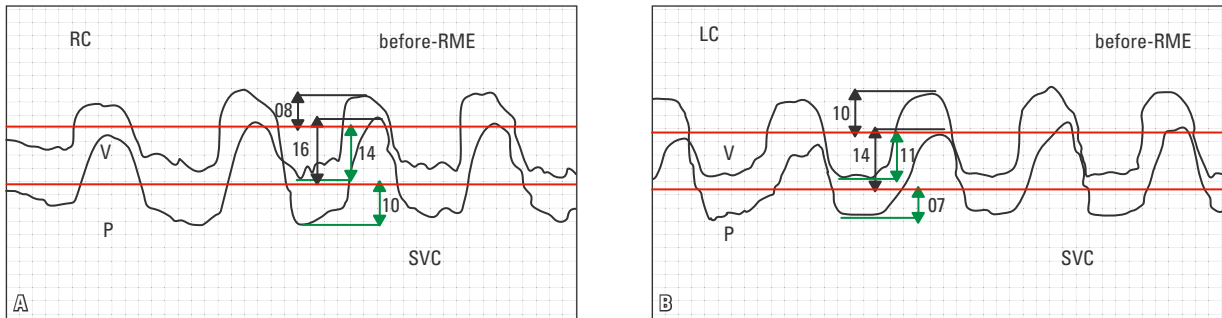


FIGURE 8 - Rhinomanometric examination trace before the rapid maxillary expansion (RME): **A)** Right nasal cavity and **B)** Left nasal cavity.

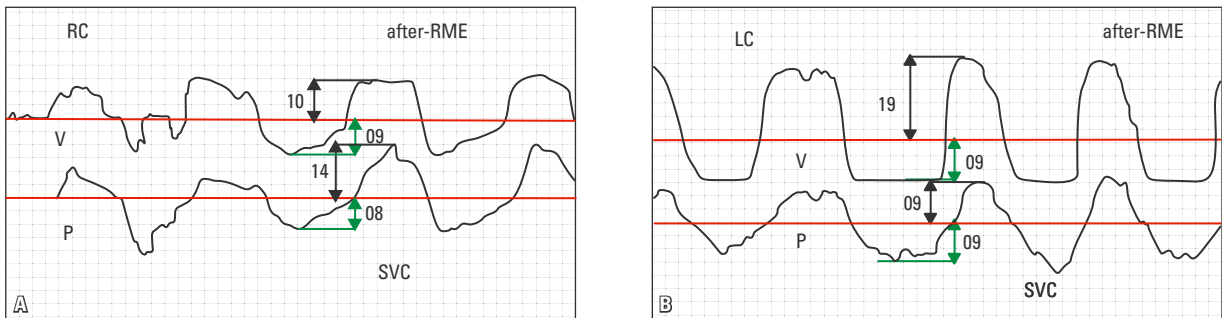


FIGURE 9 - Rhinomanometric examination trace after the rapid maxillary expansion (RME): **A)** Right nasal cavity and **B)** Left nasal cavity.

Thus, as our study was not concerned with the nasal conductance (V/P), but with the nasal resistance (P/V), the pressure: flow ratio would be 20/20 or 18/24. Therefore, normal individuals without complaints of nasal obstruction would have a unilateral nasal resistance ranging from 0.75 to 1.00 mm/H₂O/l/min.

Calculation of total nasal resistance

To calculate the total nasal resistance, the following formula was used:

$$TNR = \frac{RNR \times LNR}{RNR + LNR}$$

By this formula, the grid is equal to the right nasal resistance (RNR) multiplied by the left nasal resistance (LNR) and divided by the sum of them.^{17,18}

Thus, the total nasal resistance with and without vasoconstrictor was calculated.

Therefore, normal individuals without complaints of nasal obstruction would have a total nasal resistance ranging from 0.37 to 0.50 mm/H₂O/l/min.

FINAL COMMENTS

After (RME), a decrease in pressure (P) was observed in the right nasal cavity (RN), while the flow (F) remained constant. In the left nasal cavity (LN) a decrease in pressure (P) and an increase in the flow (F) were observed.

After the RME was completed the patient showed a reduction in nasal resistance, an event previously reported in studies in the literature.^{10,22,24,27,33} However, we must be aware that despite the benefit of the decrease in nasal resistance and thereby increase nasal patency of this orthopedic procedure, it should not be

done simply for the purpose of providing improvement in nasal function in patients with breathing difficulties, but only when it is associated to a correct indication for rapid maxillary expansion.^{10,32}

Thus, one of the purposes of this article is to emphasize that the expander, used to perform rapid maxillary expansion (RME), and correct

posterior unilateral or bilateral crossbites is its main function, but it also contributes to reduce total nasal resistance and increase nasal conductance. However, we must not forget that the examination of active anterior rhinomanometry is an important diagnostic method for evaluating the reduction of naso-respiratory function and determine the individual's breathing pattern.

REFERENCES

1. Angell EH. Treatment of irregularity of the permanent or adult teeth. Part I. *Dent Cosmos*. 1860 May;1(10):540-4.
2. Babacan H, Sokucu O, Doruk C, Ay S. Rapid maxillary expansion and surgically assisted rapid maxillary expansion effects on nasal volume. *Angle Orthod*. 2006 Jan;76(1):66-71.
3. Basciftci FA, Mutlu N, Karaman AI, Malkoc S, Küçükkolbasi H. Does the timing and method of rapid maxillary expansion have an effect on the changes in nasal dimensions? *Angle Orthod*. 2002 Apr;72(2):118-23.
4. Bicakci AA, Agar U, Sökücü O, Babacan H, Doruk C. Nasal airway changes due to rapid maxillary expansion timing. *Angle Orthod*. 2005 Jan;75(1):1-6.
5. İlan I, Oktay H. A study on the pharyngeal size in different skeletal patterns. *Am J Orthod Dentofacial Orthop*. 1995 Jul;108(1):69-75.
6. Clement PA. Committee report on standardization of rhinomanometry. *Rhinology*. 1984 Sep;22(3):151-5.
7. Cottle MH. Rhino-sphygmo-manometry: an aid in physical diagnosis. *Int Rhinol*. 1968 Aug;6(1/2):7-26.
8. Haas AJ. Rapid expansion of the maxillary dental arch and nasal cavity by opening the midpalatal suture. *Angle Orthod*. 1961 Apr;31(2):73-90.
9. Haas AJ. The treatment of maxillary deficiency by opening the midpalatal suture. *Angle Orthod*. 1965 Jul;35:200-17.
10. Hartgerink DV, Vig PS, Abbott DW. The effect of rapid maxillary expansion on nasal airway resistance. *Am J Orthod Dentofacial Orthop*. 1987 Nov;92(5):381-9.
11. Harvold EP, Tomer BS, Vargervik K, Chierici G. Primate experiments on oral respiration. *Am J Orthod*. 1981 Apr;79(4):359-72.
12. Hershey HG, Stewart BL, Warren DW. Changes in nasal airway resistance associated with rapid maxillary expansion. *Am J Orthod*. 1976 Mar;69(3):274-84.
13. Hinton VA, Warren DW, Hairfield WM. Upper airway pressures during breathing: a comparison of normal and nasally incompetent subjects with modeling studies. *Am J Orthod*. 1986 Jun;89(6):492-8.
14. Hinton VA, Warren DW, Hairfield WM, Seaton D. The relationship between nasal cross-sectional area and nasal air volume in normal and nasally impaired adults. *Am J Orthod Dentofacial Orthop*. 1987 Oct;92(4):294-8.
15. Jorge EP. Estudo das características funcionais, morfológicas e craniofaciais de pacientes com má oclusão de Classe II divisão 1ª de Angle, com predomínio da respiração bucal [dissertação]. São Paulo (SP): Universidade de São Paulo; 2000.
16. Jorge EP. Avaliação da resistência nasal total e do espaço livre bucofaringeano e nasofaringeano em pacientes com má oclusão de Classe II divisão 1ª de Angle, submetidos ao tratamento ortopédico com Bionator de Balters [tese]. Araraquara (SP): Universidade Estadual Paulista; 2006.
17. Kern EB. Committee report on standardization of rhinomanometry. *Rhinology*. 1981 Dec;19(4):231-6.
18. McCaffrey TV, Kern EB. Clinical evaluation of nasal obstruction. *Arch Otolaryngol*. 1979 Sep;105(9):542-5.
19. McNamara JA. Influence of respiratory pattern on craniofacial growth. *Angle Orthod*. 1981 Oct;51(4):269-300.
20. Melsen B, Attina L, Santuari M, Attina A. Relationships between swallowing pattern, mode of respiration, and development of malocclusion. *Angle Orthod*. 1987 Apr;57(2):113-20.
21. Moreira CA. Da avaliação rinomanométrica pré e pós-operatória em crianças portadoras de hipertrofia de vegetações adenóides [dissertação]. São Paulo (SP): Escola Paulista de Medicina; 1989.
22. Paiva JB. Estudo rinomanométrico e nasofibroendoscópico da cavidade nasal de pacientes submetidos à expansão rápida da maxila [tese]. São Paulo (SP): Universidade de São Paulo; 1999.
23. Ribak MM. Estudo rinomanométrico do fluxo, pressão e condutância em indivíduos portadores de desvio do septo nasal [dissertação]. São Paulo (SP): Universidade Federal de São Paulo; 1990.
24. Rizzato SMD. Avaliação do efeito da expansão rápida da maxila na resistência nasal por rinomanometria anterior ativa em crianças [dissertação]. Porto Alegre (RS): Universidade Católica do Rio Grande do Sul; 1998.

25. Santos-Pinto A, Paulin RF, Melo ACM, Martins LP. A influência da redução do espaço nasofaríngeo na morfologia facial de pré-adolescentes. *Rev Dental Press Ortod Ortop Facial*. 2004 maio/jun;9(3):19-26.
26. Subtelny JD. Oral respiration: facial maldevelopment and corrective dentofacial orthopedics. *Angle Orthod*. 1980 Jul;50(3):147-64.
27. Vig PS, Sarver DM, Hall DJ, Warren DW. Quantitative evaluation of nasal airflow in relation to facial morphology. *Am J Orthod*. 1981 Mar;79(3):263-72.
28. Warren DW, Hairfield WM, Seaton D, Morr KE, Smith LR. The relationship between nasal airway size and nasal-oral breathing. *Am J Orthod Dentofacial Orthop*. 1988 Apr;93(4):289-93.
29. Warren DW, Hairfield WM, Seaton DL, Hinton VA. The relationship between nasal airway cross-sectional area and nasal resistance. *Am J Orthod Dentofacial Orthop*. 1987 Nov;92(5):390-5.
30. Warren DW, Lehman MD, Hinton VA. Analysis of simulated upper airway breathing. *Am J Orthod*. 1984 Sep;86(3):197-206.
31. Watson RM Jr, Warren DW, Fischer ND. Nasal resistance, skeletal classification, and mouth breathing in orthodontic patients. *Am J Orthod*. 1968 May;54(5):367-79.
32. Wertz RA. Changes in nasal airflow incident to rapid maxillary expansion. *Angle Orthod*. 1968 Jan;38(1):1-11.
33. White BC, Woodside DG, Cole P. The effect of rapid maxillary expansion on nasal airway resistance. *J Otolaryngol*. 1989 Jun;18(4):137-43.

Submitted: February 2005
Revised and accepted: June 2009

Contact address

Edmilsson Pedro Jorge
Rua Francisco Rocha nº 1750, sala 604 - Champagnat
CEP: 80.730-390 - Curitiba / PR, Brazil
E-mail: edmilssonjorge@yahoo.com.br